

# The Use of Bidimensional Brackets in Lingual Orthodontics: New Horizons in the Treatment of Adult Patients

**Aldo Macchi**  
**Antonio Norcini**  
**Vittorio Cacciafesta**  
**Federico Dolci**

*University of Insubria – Varese  
 Faculty of Medicine and  
 Surgery  
 Department of Orthodontics  
 Varese, Italy*

**Summary:** The aim of the present report is to describe a new esthetic and inexpensive lingual technique that employs two-dimensional (2D) lingual brackets, superelastic lingual archwires, and direct bracket bonding, without a set-up. The ease of direct application of 2D lingual brackets makes it possible to achieve a good functional occlusion also in the presence of severe malocclusions, by adopting the biomechanical options offered by lingual appliances, as well as bypassing many factors that complicate conventional lingual treatment.

**Key words:** lingual orthodontics, esthetics, lingual brackets

**Reprint requests:** Prof. Dr. Aldo Macchi, University of Insubria – Varese, Via Piatti 10 – Velate, 21100 Varese, Italy. E-mail: aldo.macchi@uninsubria.it

*Submitted for publication ■■■■; accepted for publication ■■■■.*

*Orthodontics 2004; 1: 1–11.*

Please  
 supply  
 portrait  
 of  
 Author

## INTRODUCTION

Nowadays lingual technique is a successful approach in the orthodontic treatment of adult patients, although it is considered as one of the most difficult techniques, requiring long treatment times and often achieving less than satisfactory results. The greatest advantage of this technique over conventional fixed appliances is the superior esthetics (Nidoli et al., 1988).

During our initial experience in lingual orthodontics, we used the pinless Begg bracket<sup>1</sup>, which is self-ligating, but neither small enough, nor comfortable for lingual treatment. Furthermore, we faced many clinical problems controlling rotations, tipplings and sliding mechanics. Initially, we tried to achieve a better control of rotations and tipplings by employing two archwires simultaneously; subsequently, we used a slot adapter that allowed us to reduce the slot dimensions and create the moments needed for correcting rotations and tipplings. More re-

cently, in order to solve those problems, we developed a new lingual bracket with threedimensional control: the 3D N/M<sup>1</sup>, which has proved to be more comfortable for lingual treatment, and offers superior mechanical features (Fig. 1) (Macchi et al., 2002a).


In lingual orthodontics, 1st and 3rd-order tooth movements are more complicated due to the variability of the lingual tooth anatomy (Nidoli et al., 1985). Torque control is also more difficult, because of the reduced inter-bracket distance. Even small variations in bracket height can have a considerable effect on torque. These factors have led to the development of various indirect bracket-transfer methods, such as TARG<sup>2</sup> and CLASS<sup>3</sup> (Alexander et al., 1982; Nidoli et al., 1984) (Fig. 2).

On the other hand, we have developed a new inexpensive lingual technique that aims to bypass many factors that complicate lingual treatment and still provides favorable results (Tagliabue et al., 2000; Macchi et al., 2002b). The aim of this report is to present the design,

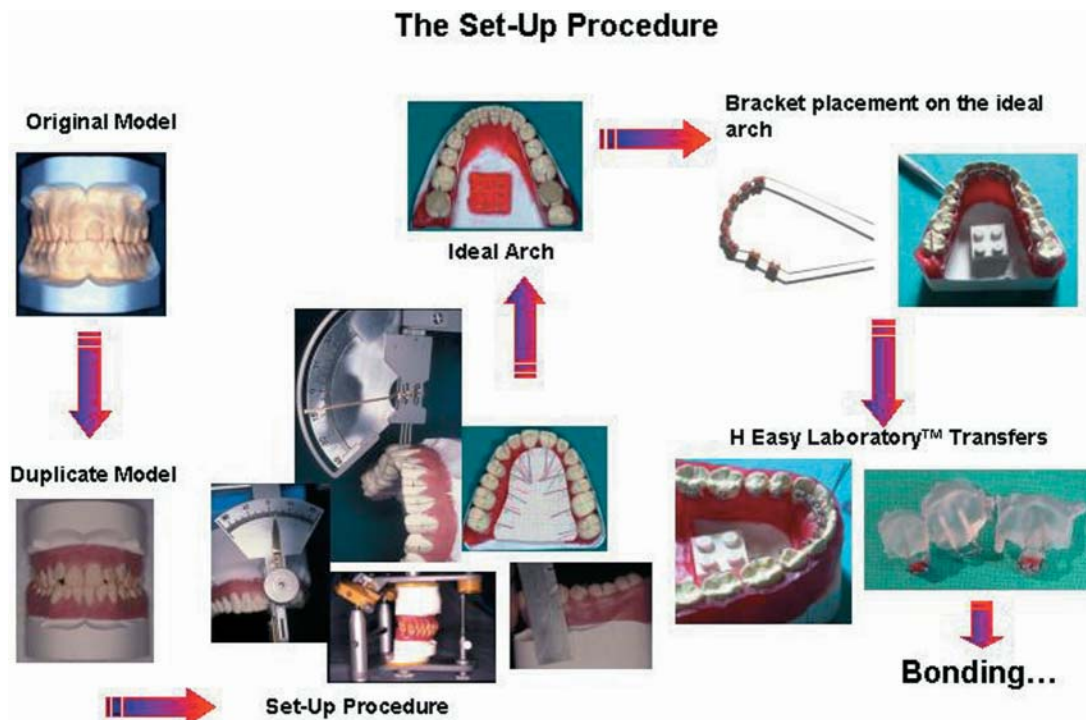
<sup>1</sup> Forestadent, Pforzheim, Germany.

<sup>2</sup> SDS/Ormco, Orange, CA, USA.

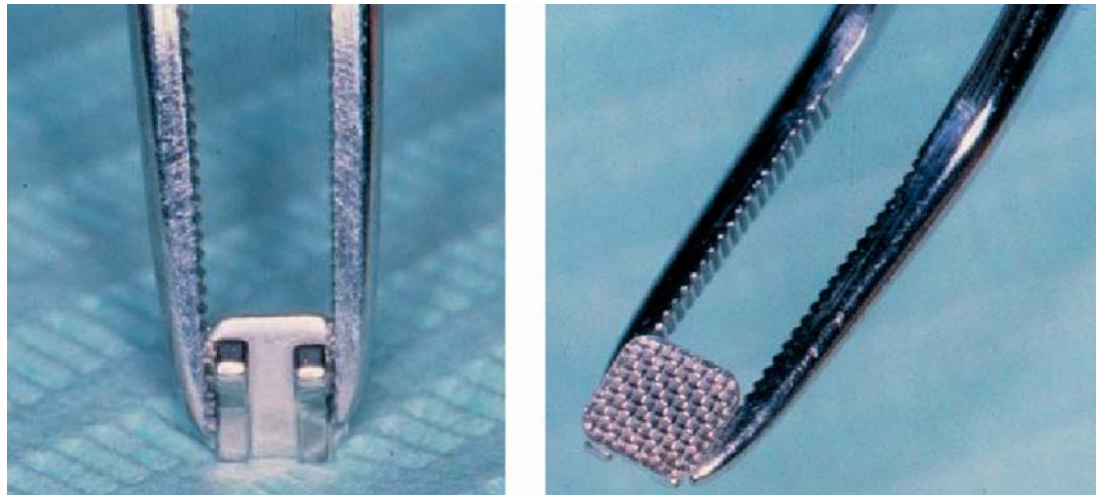
<sup>4</sup> Specialty Appliances, Norcross, GA, USA.



■ **Fig. 1** Early experiences with the pinless *Begg* bracket (left) led to the development of the 2D bracket (bottom) and the the 3D N/M bracket.



■ **Fig. 2** The set-up procedure for bonding lingual brackets indirectly is complex and expensive.



■ Fig. 3 2D lingual bracket.

characteristics and clinical applications of a two-dimensional lingual bracket (no 3rd-order control) that can be bonded directly to the lingual tooth surfaces and which is the keystone of the Insubria system.

#### **Insubria system™**

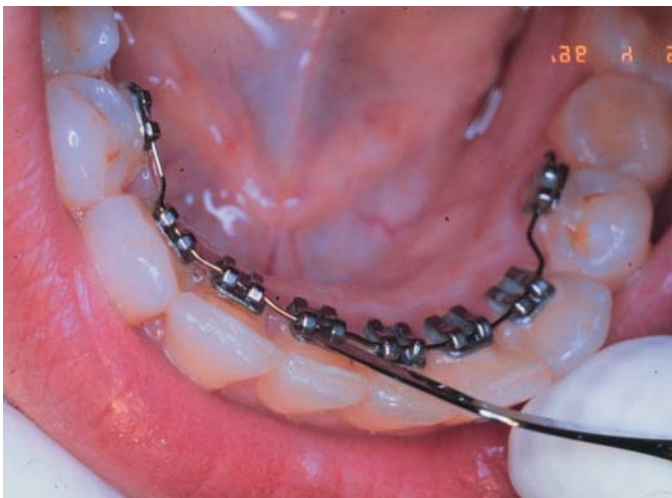The Insubria system™ lingual technique consists of:

- 2D lingual brackets,
- Titanol superelastic lingual archwires,
- light wire mechanics,
- light forces and power chains,
- direct bonding (without any need of an ideal set-up).

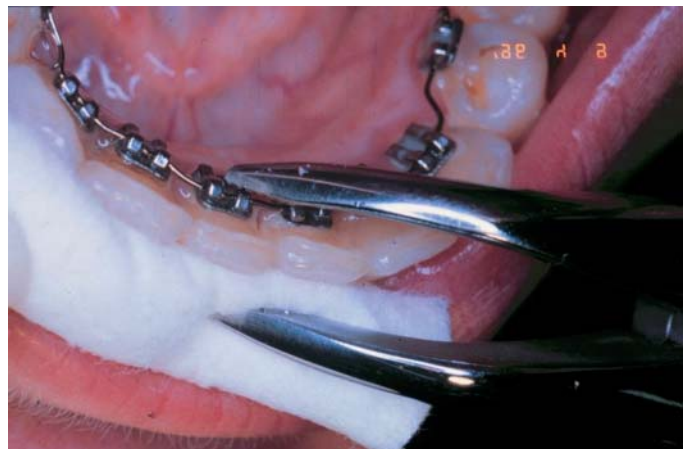
This type of system offers: excellent comfort for the patients seeking maximum esthetics,

- shorter treatment time,
- easy clinical management,
- reduced chair working time,
- low costs.

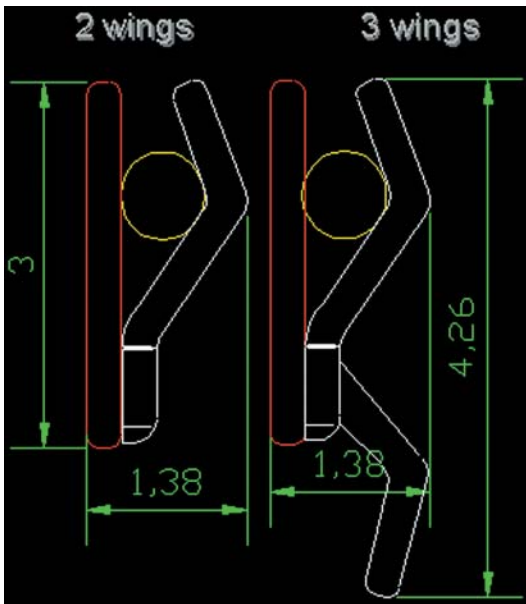
The Insubria system™ consists of a simple self-ligating lingual bracket<sup>1</sup>, which does not have a traditional rectangular slot in the base but two wings on the lingual surface to trap the archwire (Fig. 3). Since the brackets do not have slots, only 1st and 2nd-order movements are possible. These wings may be opened with a *Heidemann* spatula, which has been



■ Fig. 4 Opening brackets with a customized *Heidemann* spatula.



■ Fig. 5 Closing bracket wings with a *Weingart* plier.



■ **Fig. 6** Dimensions of the 2D lingual brackets.

previously customized by thinning the ends with a grinder, which allows the archwire to be inserted into the wing-slot, or to be removed from it (Fig. 4). Brackets are easily closed with *Weingart* pliers; we suggest closing only one wing at a time to reduce the risk of accidental debonding. A cotton roll should be held against the labial surfaces of the teeth to avoid any slipping of the pliers (Fig. 5). Removal of brackets at the end of orthodontic therapy is easily accomplished with lingual *Weingart* pliers.

### **Main characteristics of the 2D lingual bracket**

Two types of two-dimensional lingual brackets are available: a standard medium twin, and a three-wing bracket (Fig. 6 and 7).

The first type has two wings soldered to the bracket base, making it ductile enough to be opened and closed during the entire course of treatment in order to insert and trap the wire. The wire insertion is vertical, thus allowing for good control of rotations, tipplings, but without any torque control (Fig. 8).

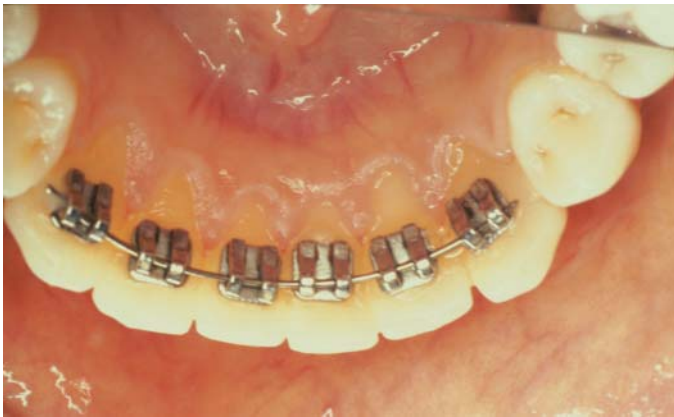The other type is a three-wing bracket that is indicated for more complex treatments, because it allows a better management of elastic chains, intermaxillary elastics, and the use of auxiliary springs for simple 3rd-order movements (Fig. 9).

The common features of the two types of brackets are the base and the system that engages the wire. The base, which is highly retentive, has a thickness of 0.4 mm and is manufactured in order to allow the bracket to be positioned almost at the level of the cingulum of front teeth, i. e. (for incisors with correct torque) on the projection of the center of resistance (Fig. 10 a and b).

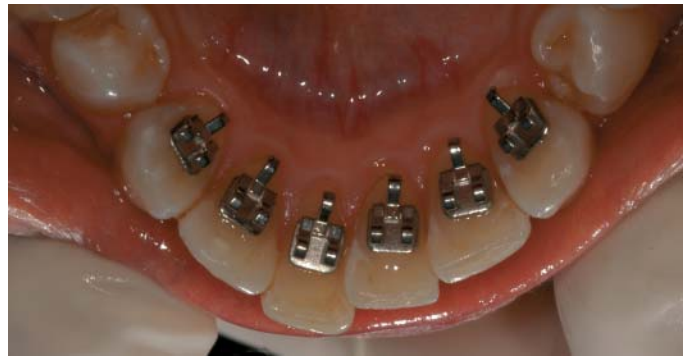The absence of the slot in the base has made it possible to reduce the total thickness of the bracket to only 1.4 mm, which allows the archwire to be almost tangential to the lingual surfaces. In order to compensate for the different labio-lingual thickness normally present on the front teeth, particularly in the maxillary



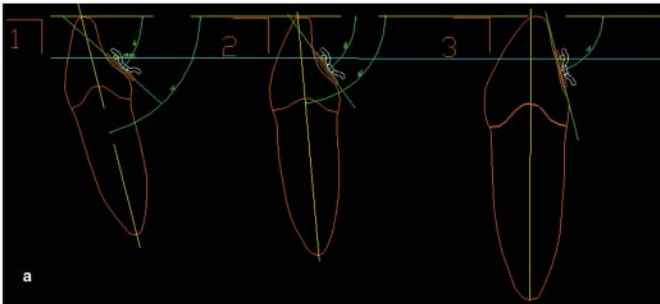
■ **Fig. 7** Different types of 2D lingual brackets: standard medium twin (left), and 3-wing bracket (right).



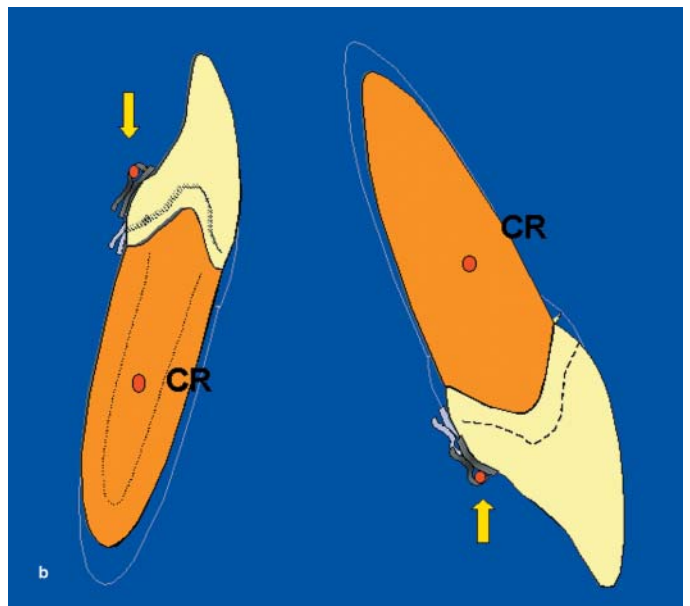
■ Fig. 8 Clinical use of 2-wing brackets.



■ Fig. 9 Clinical use of 3-wing brackets.



■ Fig. 10 a and b Brackets are positioned almost at the level of the cingulum of front teeth (a), that is (for incisors with normal torque) on the projection of the center of resistance (b).



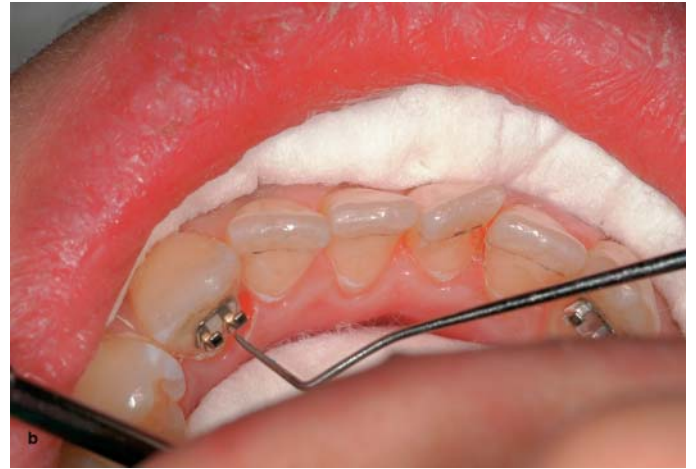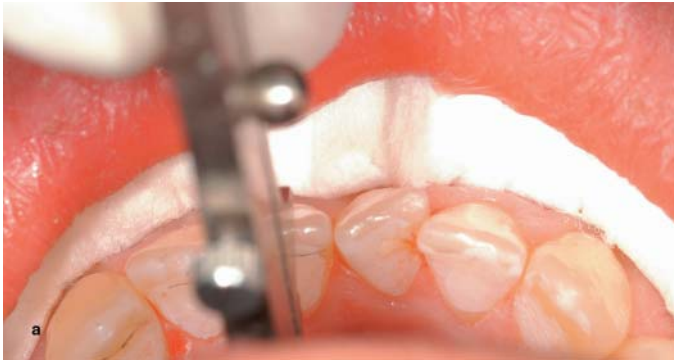arch, a 1st-order bend is usually needed between lateral and canine.

To summarize 2D lingual bracket

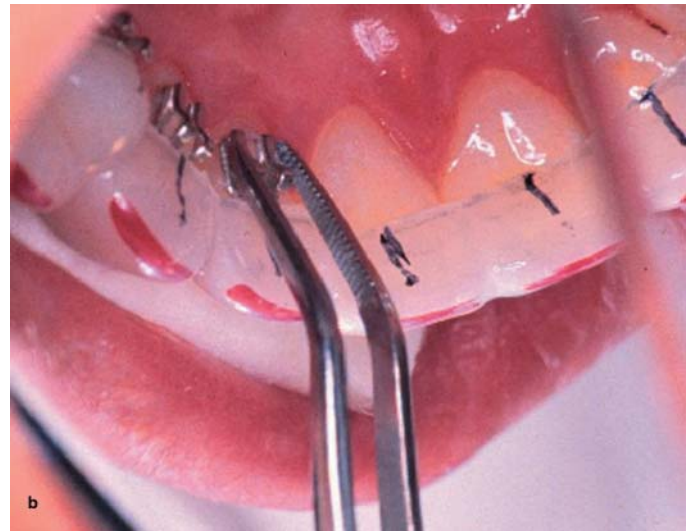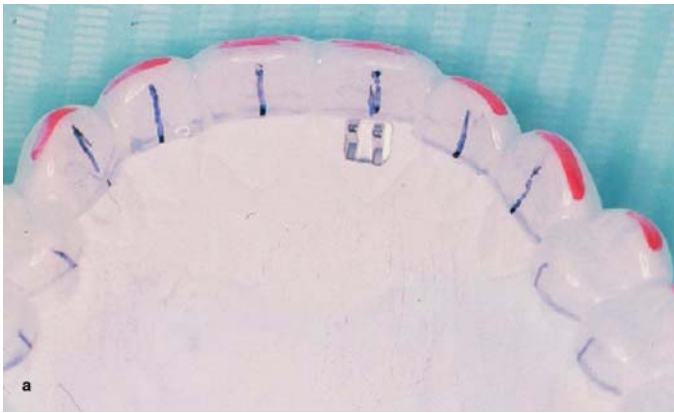
- can be used for all teeth,
- allows a vertical insertion of the archwire,
- does not have a rectangular slot, which is replaced by two wings able to trap the wire,
- is self-ligating, with progressive friction, which can be regulated by pressing the wings
- is able to engage round wires with a maximum diameter of .016"
- has a total thickness of 1.4 mm, including the base (0.4 mm) (Fig. 6)
- allows the use of power chains with a maximum thickness of 0.5 mm.

In the mandibular arch, direct bonding is performed using a universal placement gauge to mark the desired height from the incisal edge (Fig. 11 a and b). In the maxillary arch, because of the more complex anatomy and limited visibility, we suggest the use of a vacuum-formed soft sheet<sup>4</sup> as a reference guide. This sheet does not hold the brackets. Bracket inclinations can be indicated on the tray by marking the long axes of the teeth. This system will allow brackets to be positioned at the correct height, thus avoiding occlusal interferences from the overbite (Fig. 12 a and b).

<sup>4</sup>Copyplast, Scheu-Dental, Iserlohn, Germany.



■ **Fig. 11 a and b** Marking the vertical bracket position in the mandibular arch with a placement gauge (a) and subsequent direct bonding (b).




■ **Fig. 12 a and b** Bonding in the maxillary arch with the use of a vacuum-formed soft sheet as a reference guide on plaster model (a) and in the mouth (b).

### ***Main characteristics of the lingual archwires***

The wires normally used in combination with the 2D brackets are preformed Titanol lingual archwires<sup>1</sup> in 3 classic shapes (small, medium, large; with diameters of .012", .014", and .016") (Fig. 13). These archwires are pre-curved from canine to canine, both for the maxillary and mandibular arch, and allow a precise insertion of a 1st-order bend between canine and first premolar in order to produce the typical mushroom arch configuration (Fujita, 1979). We have developed a method for adding simple 1st or 2nd-order bends to the preformed archwire by over-bending the wire with either 3-prong or bird-

beak pliers, while it is in its martensitic (cold) phase. If the wire is then gently heated with a flame (up to approximately 60–70°C), it will regain its austenitic phase, and the effective amount of bending can be checked (Fig. 14 a and b). This is a very easy clinical procedure that requires only a few minutes of chair working time.

The use of Titanol archwires enables the clinician to produce low levels of applied force and to achieve a more consistent tooth movement during the first phase of treatment (leveling and aligning), because those wires have a wide range of deactivation, thus significantly reducing the number of appointments and reactivations.



■ **Fig. 13** Preshaped Titanol lingual archwires.

### **Clinical Applications**

The 2D lingual brackets can be effectively used for:



- Post-treatment retention
- Closure of minor spaces and diastemata (Fig. 15 a and b)
- Limited correction of deep bites (Fig. 16 a and b)
- Correction of simple tooth misalignments

and mild crowding, particularly in the mandibular arch (Fig. 17 a and b)

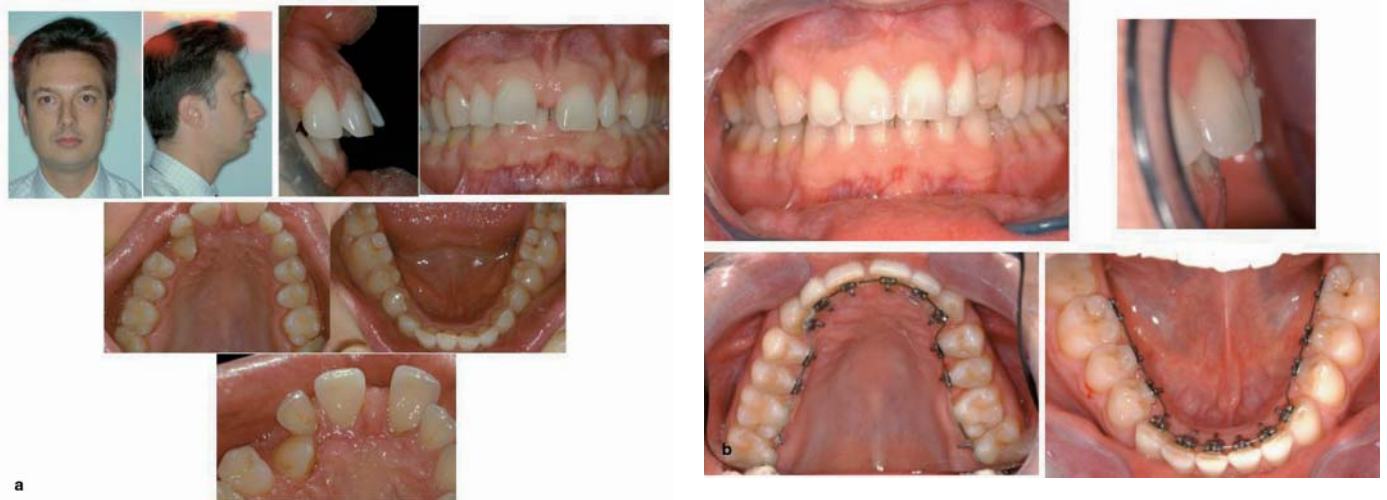- Correction of anterior cross bites (Figs. 18 a and b, 19 a to e).

### **CONCLUSIONS**

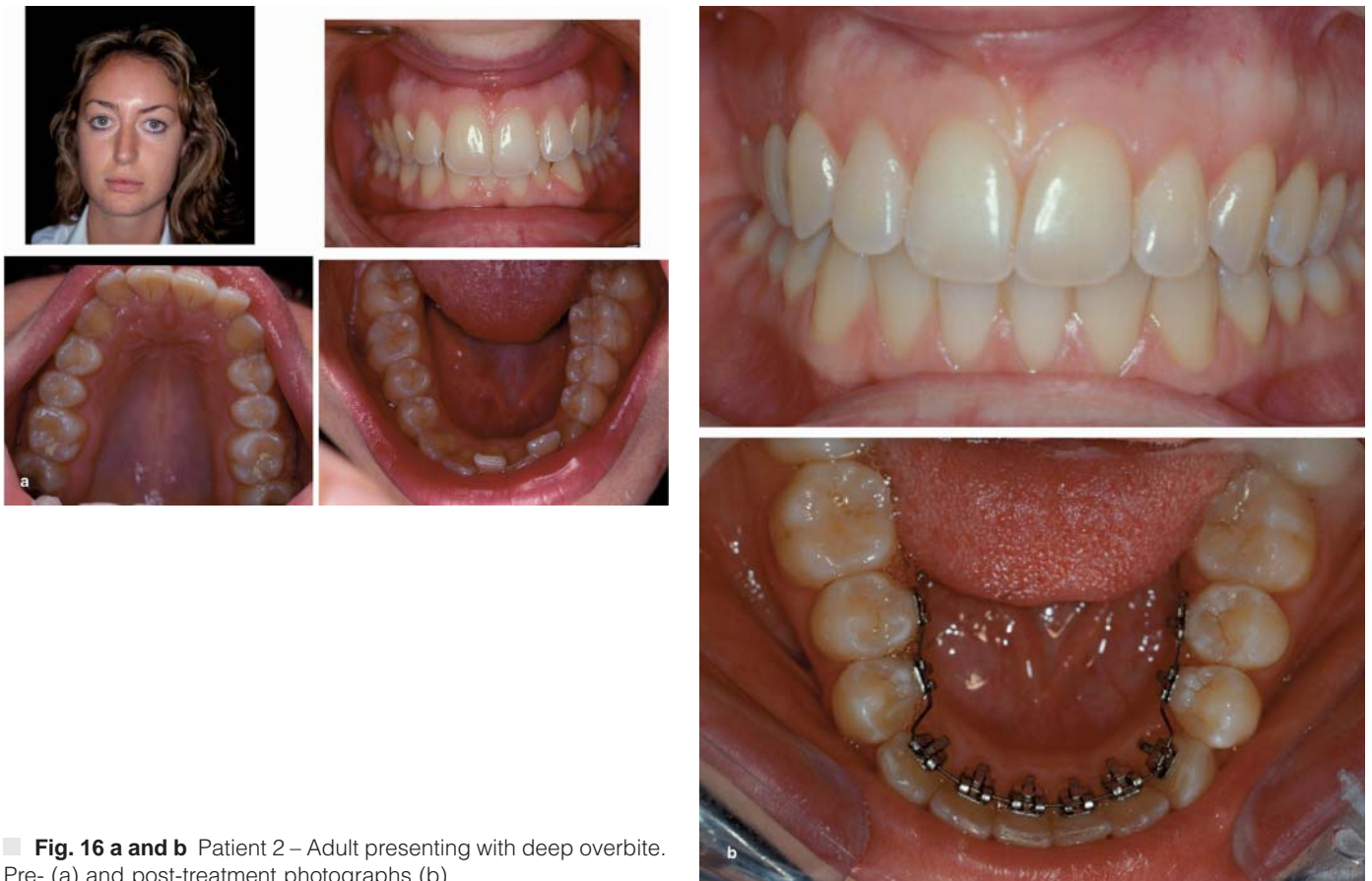Lingual orthodontics demands special biomechanical expertise and technical skills,



■ **Fig. 14 a and b** Bending superelastic Titanol wires: First bend – overbend the wire while it is in its martensitic phase (a). Then, check the effective amount of bending by gently heating it with a flame (b).



■ **Fig. 15 a and b** Patient 1 – Adult presenting with an anterior diastema, increased overjet and overbite plus cross bite of the maxillary right canine. Pre- (a) and post-treatment photographs (b).

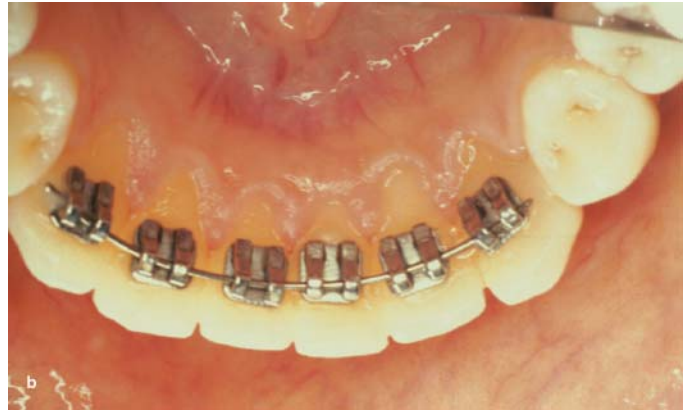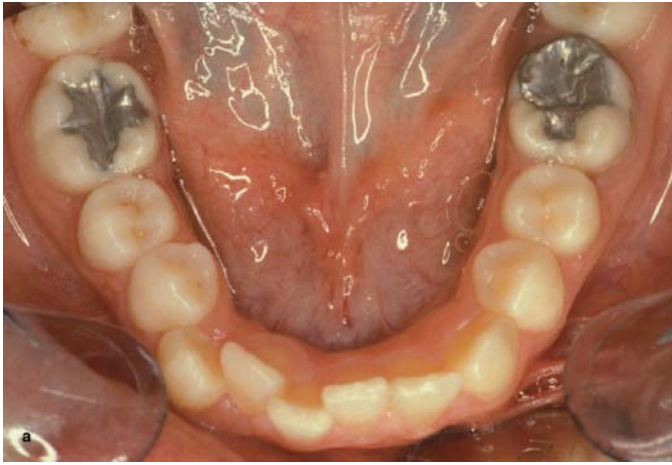


■ **Fig. 16 a and b** Patient 2 – Adult presenting with deep overbite. Pre- (a) and post-treatment photographs (b).

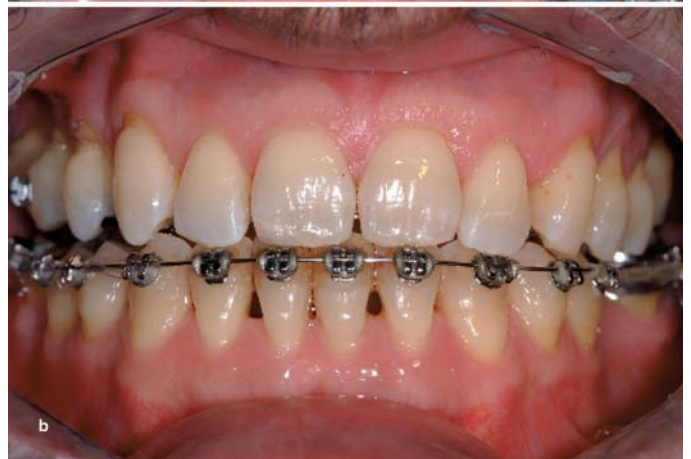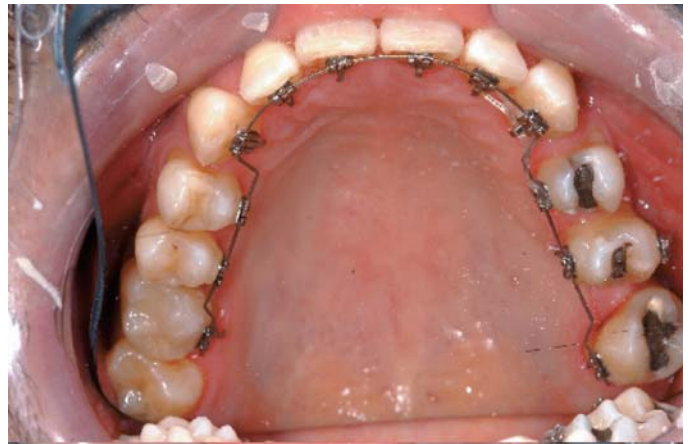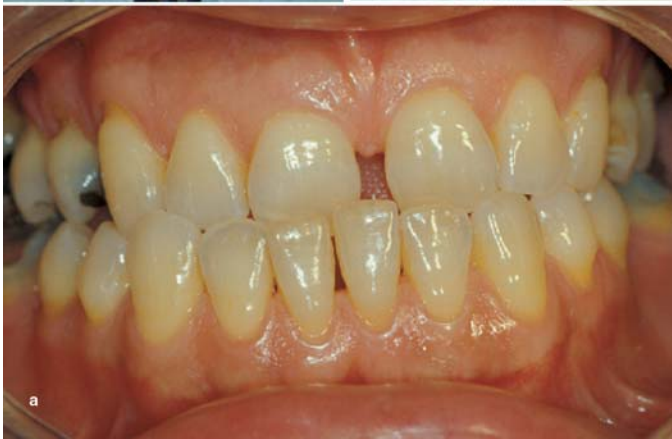such as indirect bracket bonding and customized arch bending. However, bidimensional lingual brackets are a valid alternative to con-

ventional lingual brackets in adult cases that do not require 3rd-order tooth movements. Indications for using those brackets are repre-





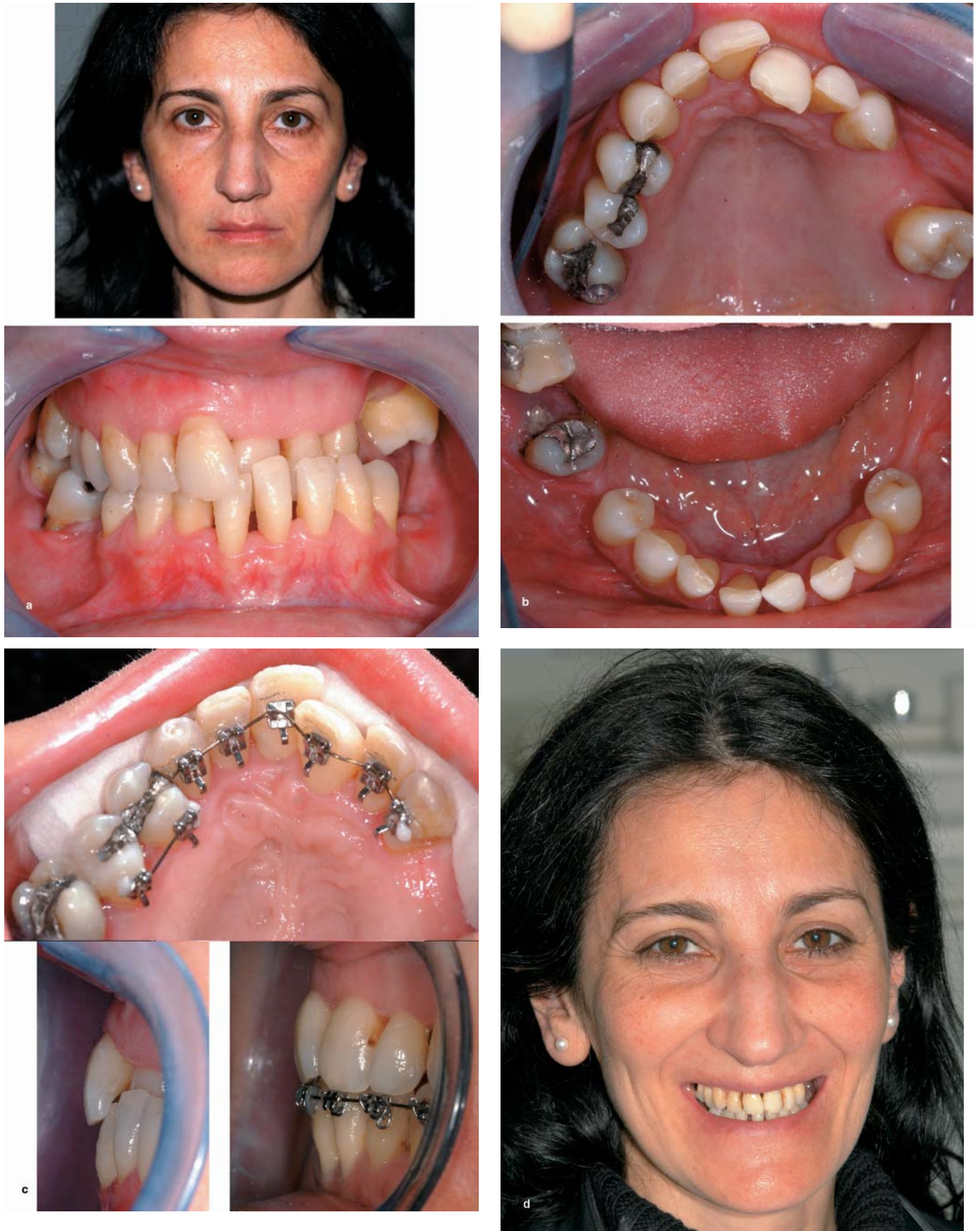**Fig. 17 a and b** Patient 3 – Adult presenting with mandibular crowding. Pre- (a) and post-treatment photographs (b).

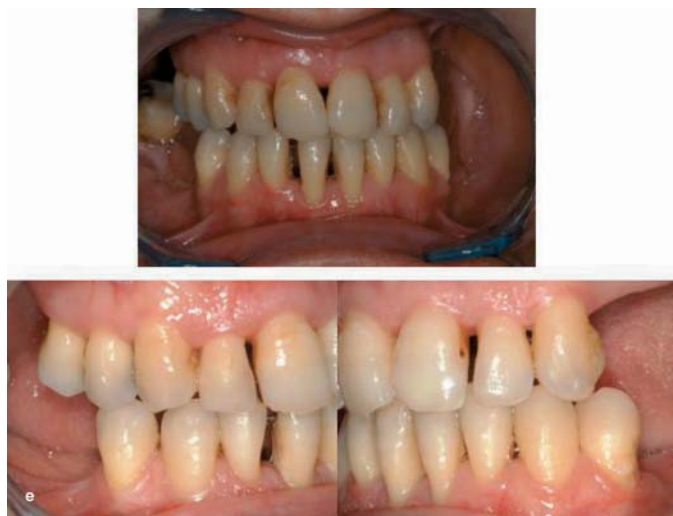

**Fig. 18 a and b** Patient 4 – Adult presenting with anterior cross bite and diastema. Pre- (a) and post-treatment photographs (b).

sented by post-treatment retention, closure of minor spaces, limited correction of deep bite, correction of mild crowding, particularly in the mandibular arch, and correction of anterior cross bite.

Once a clinician's familiarity with the lingual technique described above has improved, he or she will be able to treat more difficult cases with more sophisticated 3D brackets and indirect bonding.





■ **Fig. 19 a–e** Patient 5 – Adult presenting with severe anterior cross bite. Pre- (a–b) and post-treatment photographs (c–e).

## REFERENCES

- Alexander CM, Alexander RG, Gorman JC, Hilgers JJ, Kurz C, Scholz RP, Smith JR: Lingual orthodontics: a status report. *J Clin Orthod* 16: 255–262, 1982.
- Fujita K: New orthodontic treatment with lingual bracket mushroom archwire appliance. *Am J Orthod* 76: 657–675, 1979.
- Macchi A, Norcini A, Tagliabue A. Primeras experiencias con los nuevos brackets linguales 3D N/ M. *Ortod Clin* 5: 154–160, 2002a.
- Macchi A, Tagliabue A, Levrini L, Trezzi G: Philippe self-ligating lingual brackets. *J Clin Orthod* 36: 42–45, 2002b.
- Nidoli G, Lazzati M, Macchi A: Applicazione diretta o indiretta dei bracket linguali. *Mondo Ortod* 9: 63–72, 1984.
- Nidoli G, Lazzati M, Macchi A: Migliora l'estetica con l'incollaggio linguale dei bracket. *Attual Dent* 18: 12–20, 1988.
- Nidoli G, Lazzati M, Macchi A, Castoldi A: Analisi clinico-statistica della morfologia dentale in rapporto al posizionamento dei bracket linguali. *Mondo Ortod* 10: 45–53, 1985.
- Tagliabue A, Levrini L, Macchi A: Attacchi linguali Philippe: considerazioni cliniche. *Mondo Ortod* 25: 187–192, 2000.